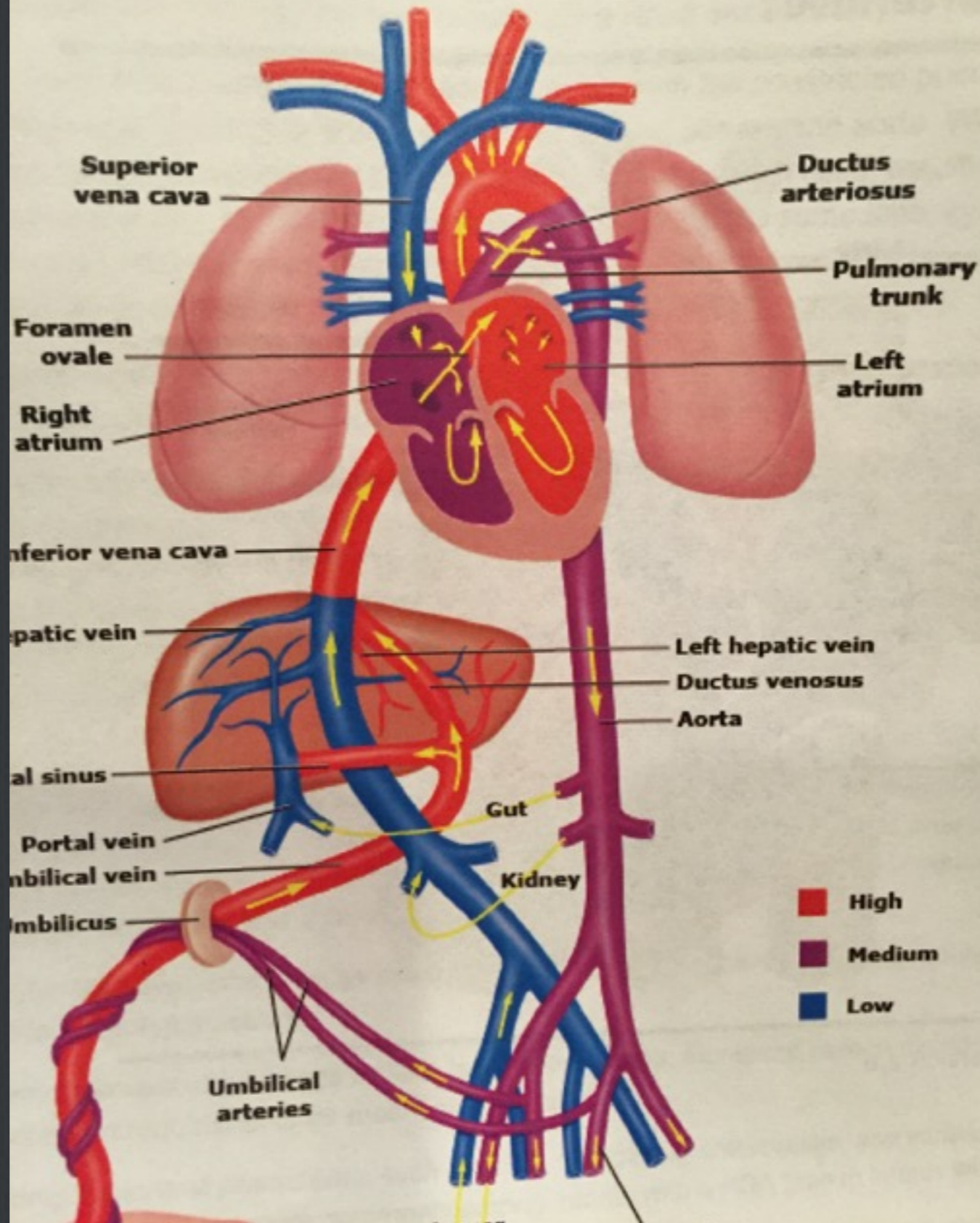


A Brief History of the Patent Ductus Arteriosus (PDA)

**Joseph Ludwick, M.D.
April 22, 2017**

ulation



What does that DA do?

- Lungs aren't doing much in utero.
- RV pumps most of its blood through the DA to the descending aorta and placenta.
- Prostaglandin E2 concentrations are high in the fetus.

DUCTUS DESCRIPTION

- Described in the early first century by Galen.
- In 16th Century, the ductus was better described and understood.
- Late 19th and 20th centuries saw extremely detailed description of the PDA and congenital heart disease. Atlas of Congenital Heart Disease by Maude Abbott, 1936.

Physiologic Effects and Clinical Implications

- Additional work of LV in maintaining peripheral blood pressure may lead to cardiac decompensation.**
- Bacterial endarteritis.**
- Excessive pulmonary circulation: pulmonary edema, pulmonary hemorrhage, chronic lung disease.**
- Hypoperfusion (ductal steal) of systemic circulation: cerebral blood flow reduced, necrotizing enterocolitis.**

Ok. So let's get that DA closed.

- Operative ligation first performed successfully in 1938. Robert E. Gross.**
- Animal studies. Positive benefits after closing the PDA.**
- First cath closure in 1971.**
- 1970s. Small studies showing successful PDA closure with Indomethacin.**
 - Friedman, et al. Sept 1976. 6 premies successfully treated.**
 - Larger studies followed showing up to 75% success rate with very few side effects.**

The Success Story

- First attempt by Dr. John Streider on 22 year old woman with endocarditis. Survived the operation but died few days later.**
- Dr. Robert Gross successfully ligated the PDA of a 7 year old girl at Children's Hospital of Boston on August 26, 1938,**
- And than many more operations followed.**

The Story

- Dr. Robert Gross**
 - From Baltimore, Maryland. Son of a piano maker.**
 - His father encouraged him to tinker and use his hands.**
 - As Chief Resident in Surgery at Boston's Children's Hospital, under Dr. William Ladd, Surgeon-in-Chief, he seized an opportunity.**

The Patient

- 7 year old, Lorraine Sweeney**
 - youngest of 8 children born to Irish immigrants.**
 - Weak, tired easily. Parents noticed constant “buzzing” from her chest.**
 - Father had been killed by a car only a few months earlier.**
 - As of 2013, doing well. 2 children, 3 grandchildren.**

The Operation

- The admission and hospital stay.
- Anesthesia. Cyclopropane by mask. Betty Lank, nurse anesthetist.
- 3rd intercostal space. PDA 7-8 mm in diameter, 5-6 mm in length. "A thrill of extreme magnety."
- Silk tie. BP changed from 110/35 to 125/90. Room seemed to suddenly become still.

The follow up

- Dr. Gross fired. Later became Surgeon-in-Chief at Children's Hospital in Boston in 1947.**
- Improved operation. Ligated 1610.**
- Turned down Dr. Taussig's proposal to surgically create a shunt.**
- Lorraine and Dr. Gross kept in touch. "your wee heart girl."**

Catheter Closure

- Coil occlusion.**
- New and better devices.**
- Improved delivery systems.**
- Few complications.**

Neonates and PDA

- Mid 1970's saw introduction of Indomethacin therapy.
- But controversy rules the day. Role of PDA in clinical presentation is being questioned.

Timing Trials.

- Watch and see.
- Prophylactic Trials.
- Symptomatic Treatment.

Spontaneous Closure

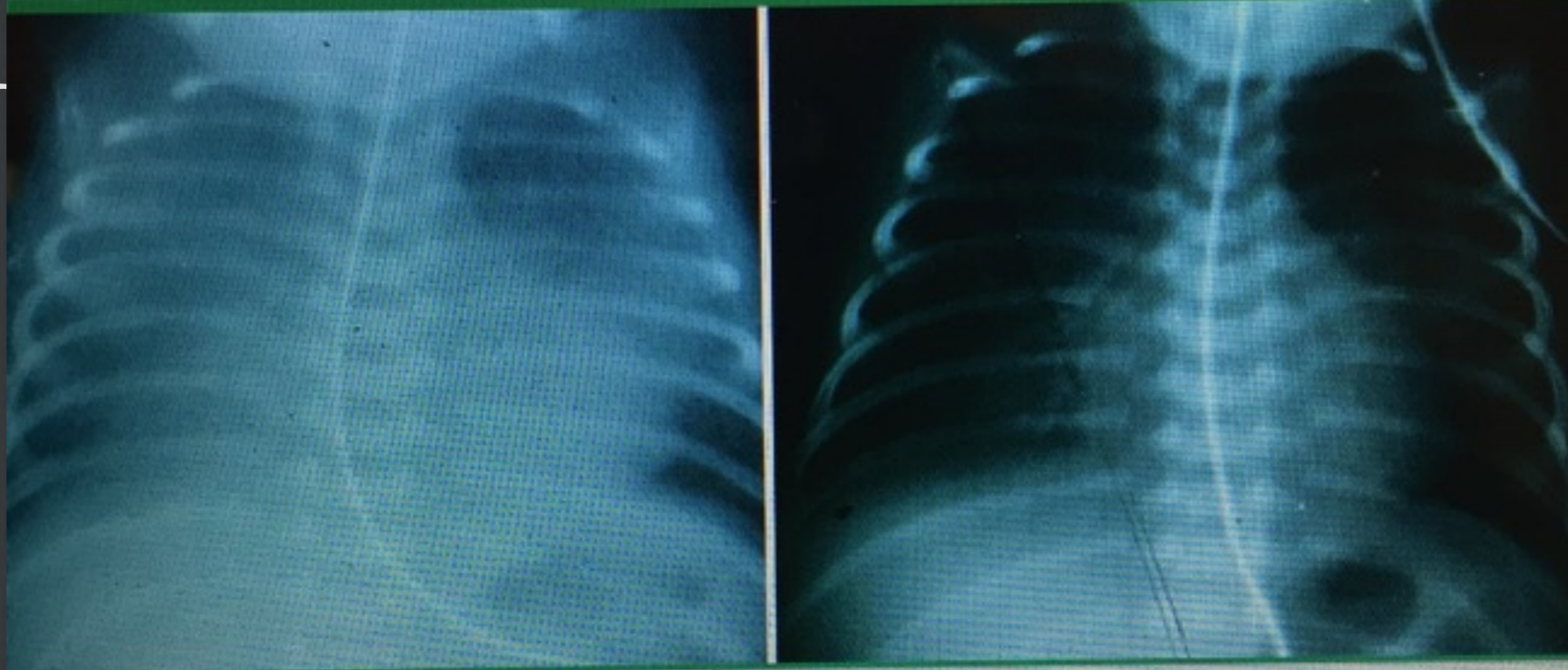
- University of Texas Southwestern Medical Center, Dallas. 2006.
- 122 neonates with BW 794 +/- 118 gms.
- Spontaneous DA closure occurred in 42 (34%) of neonates.

-
- Out of the 122 neonates, 68 were treated with Indomethacin at 6.2 +/- 4 days of life. 41% failed.**
 - Failure of Indomethacin often related to younger gestational age.**
 - Failure of Indomethacin also appeared to be related to how far out from birth baby is treated.**

Yes. There is a duct. But tell me more.

- Ductus Arteriosus Diameter. Some room for error. 1.5 mm diameter talked about a lot.**
- LV size. Direct measurements. Comparing serial echoes.**
- Function.**
- Other information: respiratory status, acid/base status, renal status, GI status, BNP.**

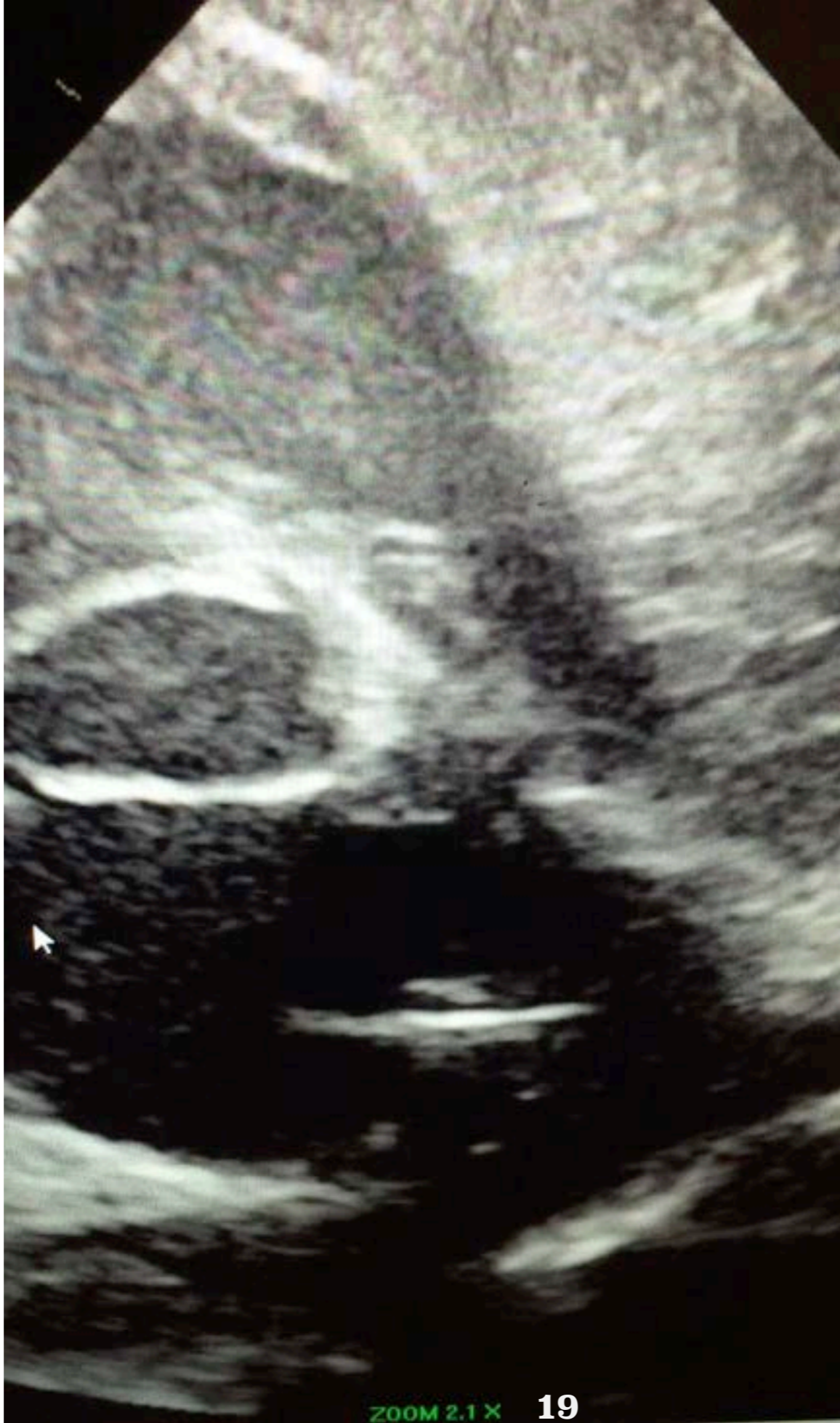Patent ductus arteriosus in preterm infant before and after indomethacin therapy

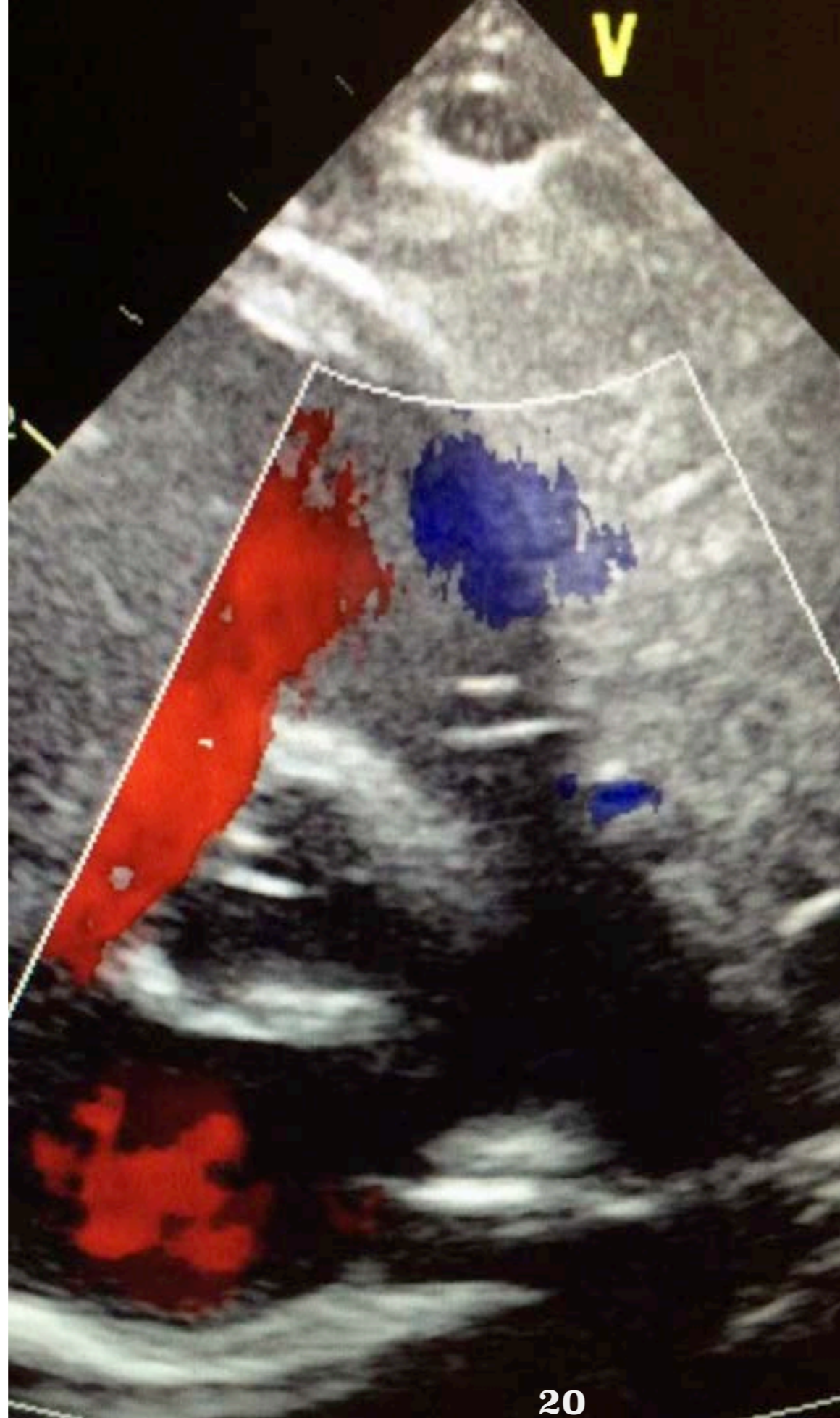

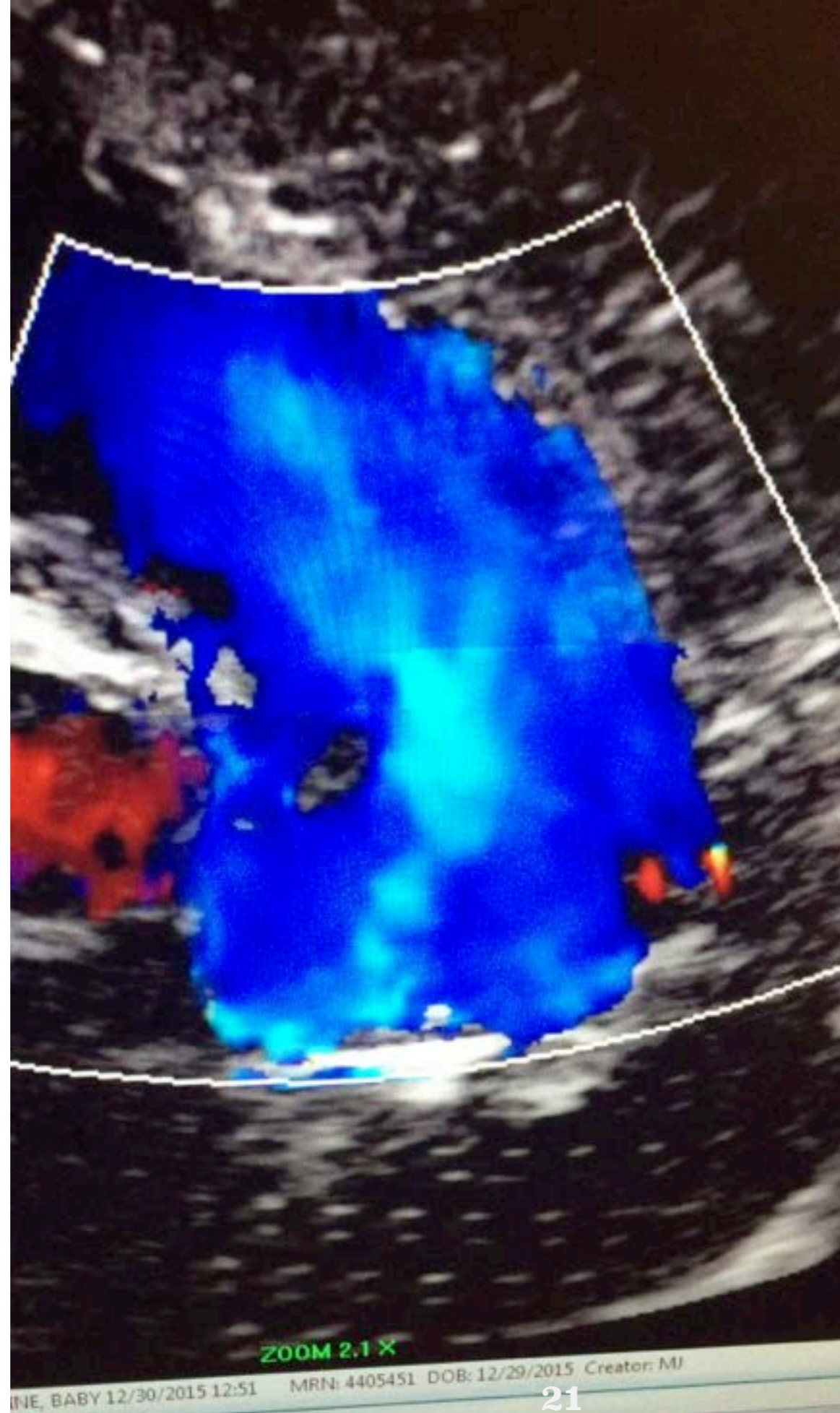
Chest radiographs from a premature infant with a symptomatic patent ductus arteriosus (PDA) before (left panel) and after (right panel) the administration of indomethacin. Prior to therapy, the lungs are opacified due to pulmonary edema resulting from increased blood flow through the PDA; the heart is also mildly enlarged. After therapy, the lung fields are clear and heart size is smaller.

Courtesy of Stephen E Welty, MD.

Graphic 71213 Version 3.0

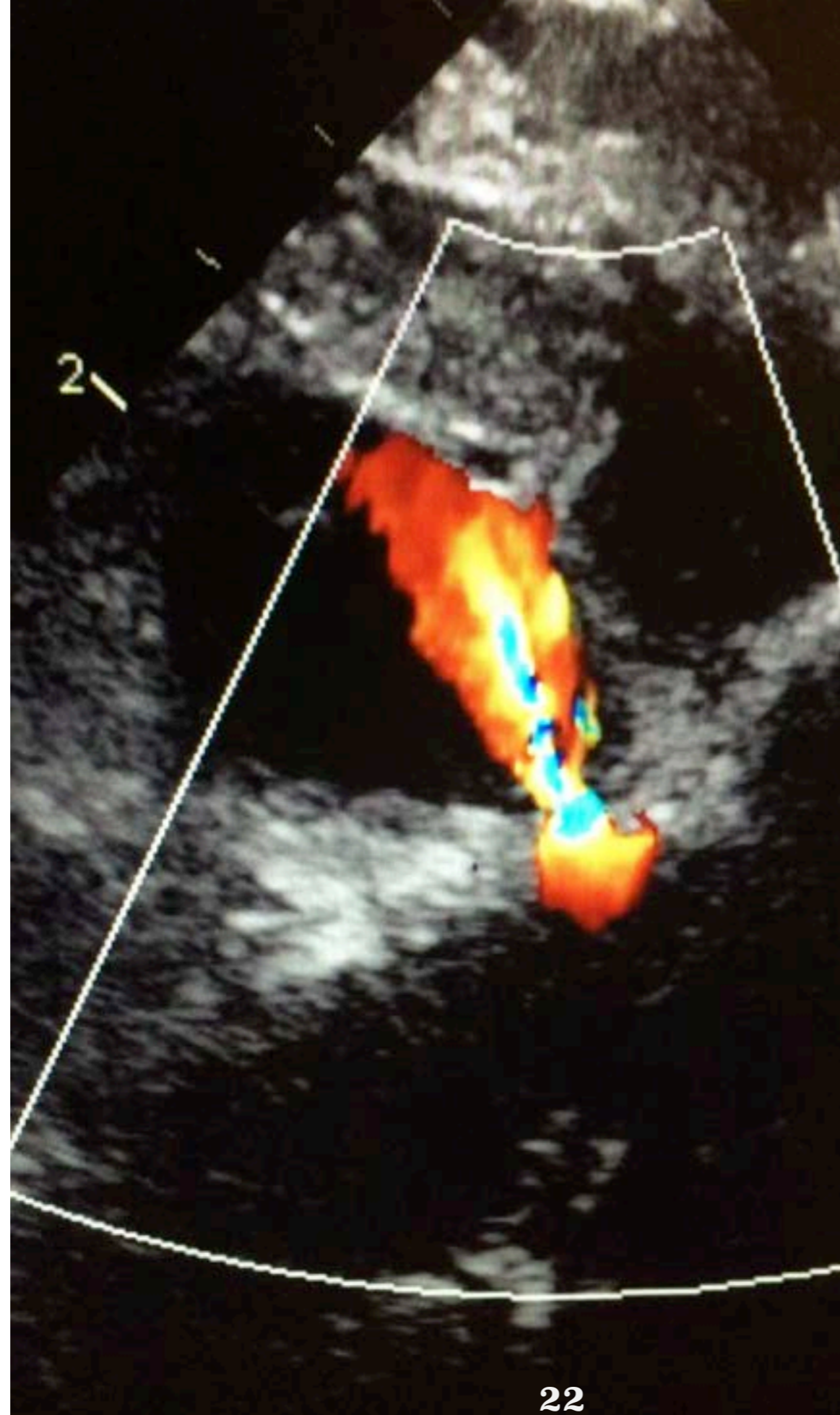


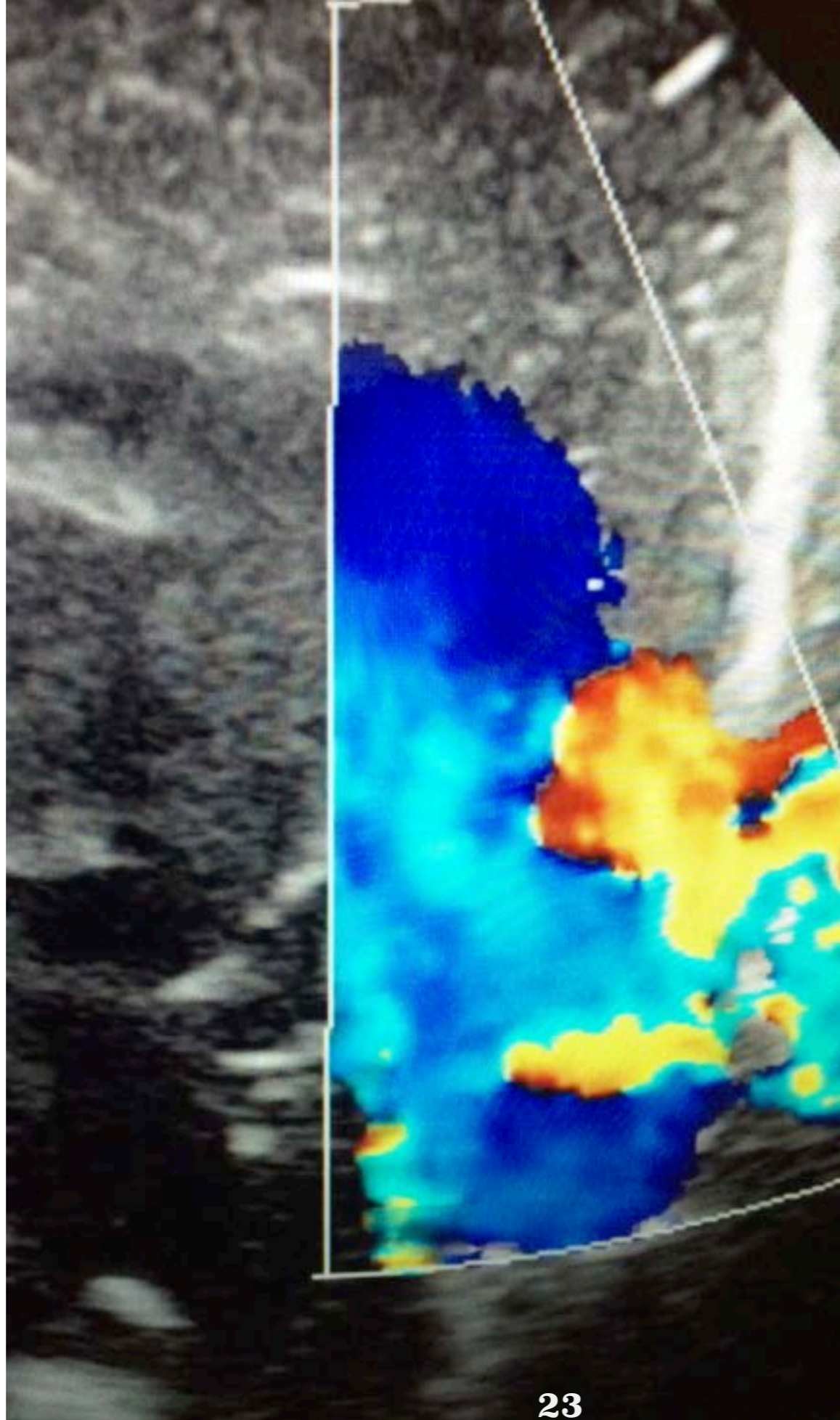




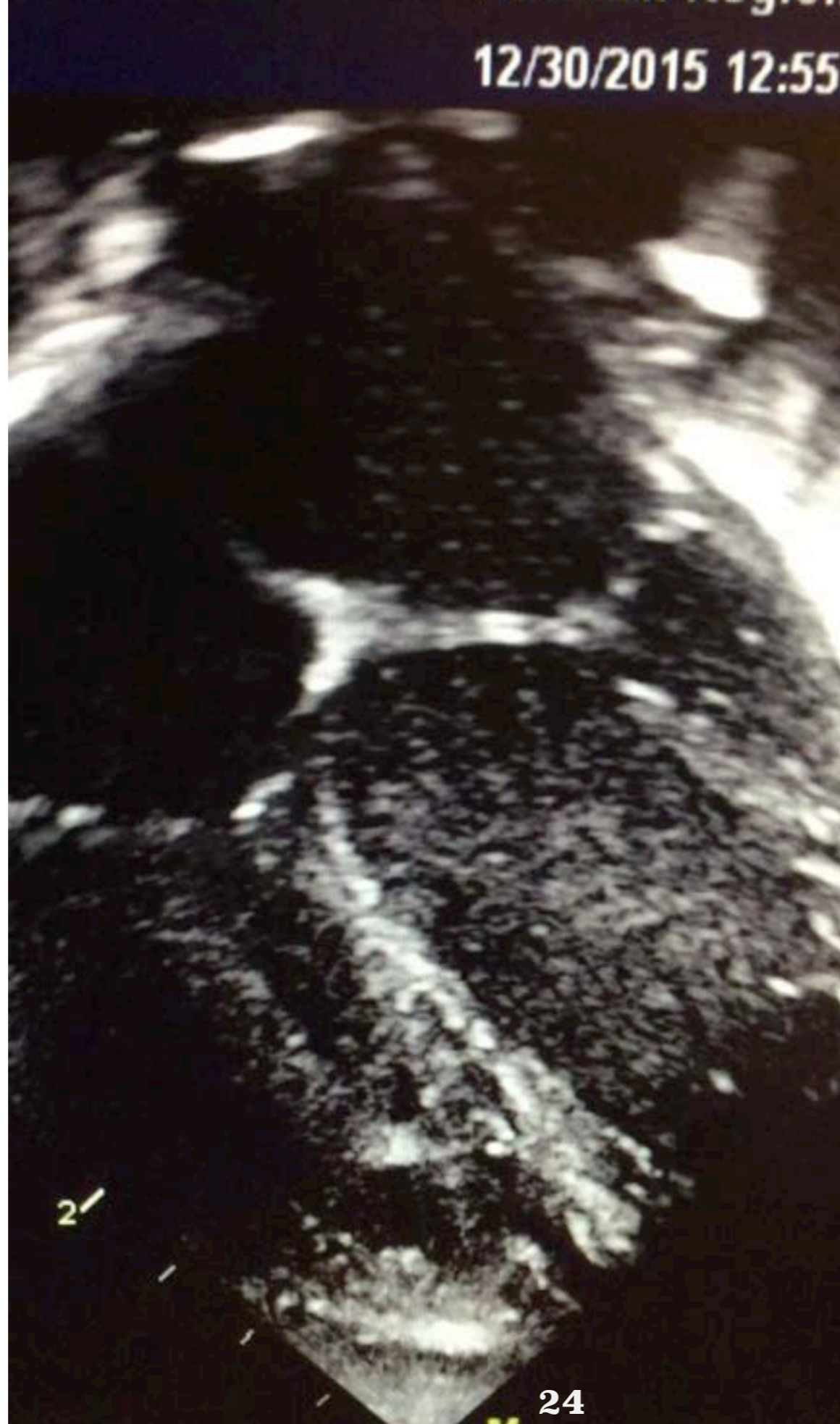ZOOM 2.1 X

INE, BABY 12/30/2015 12:51 MRN: 4405451 DOB: 12/29/2015 Creator: MJ





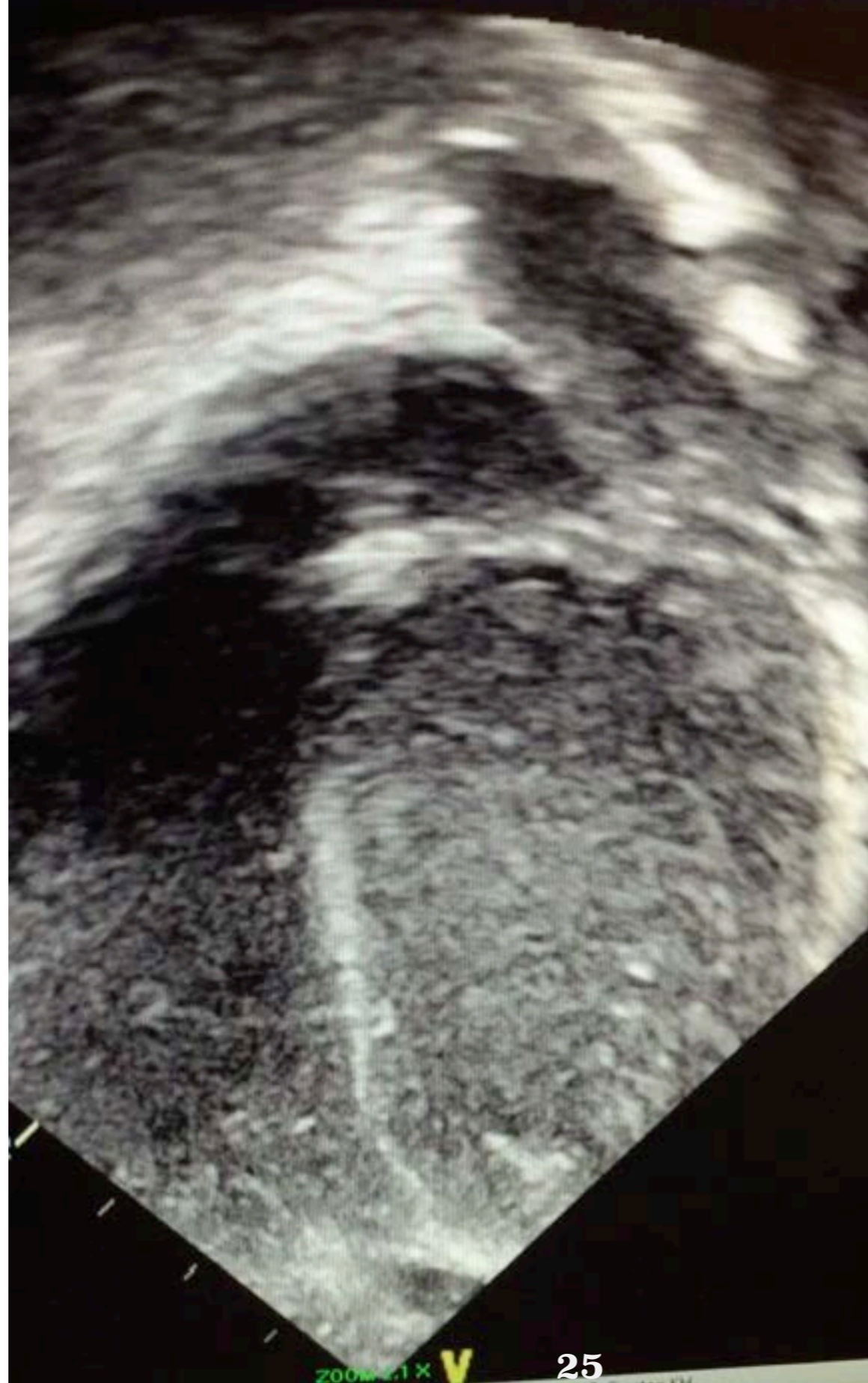
12/30/2015 12:55



2✓

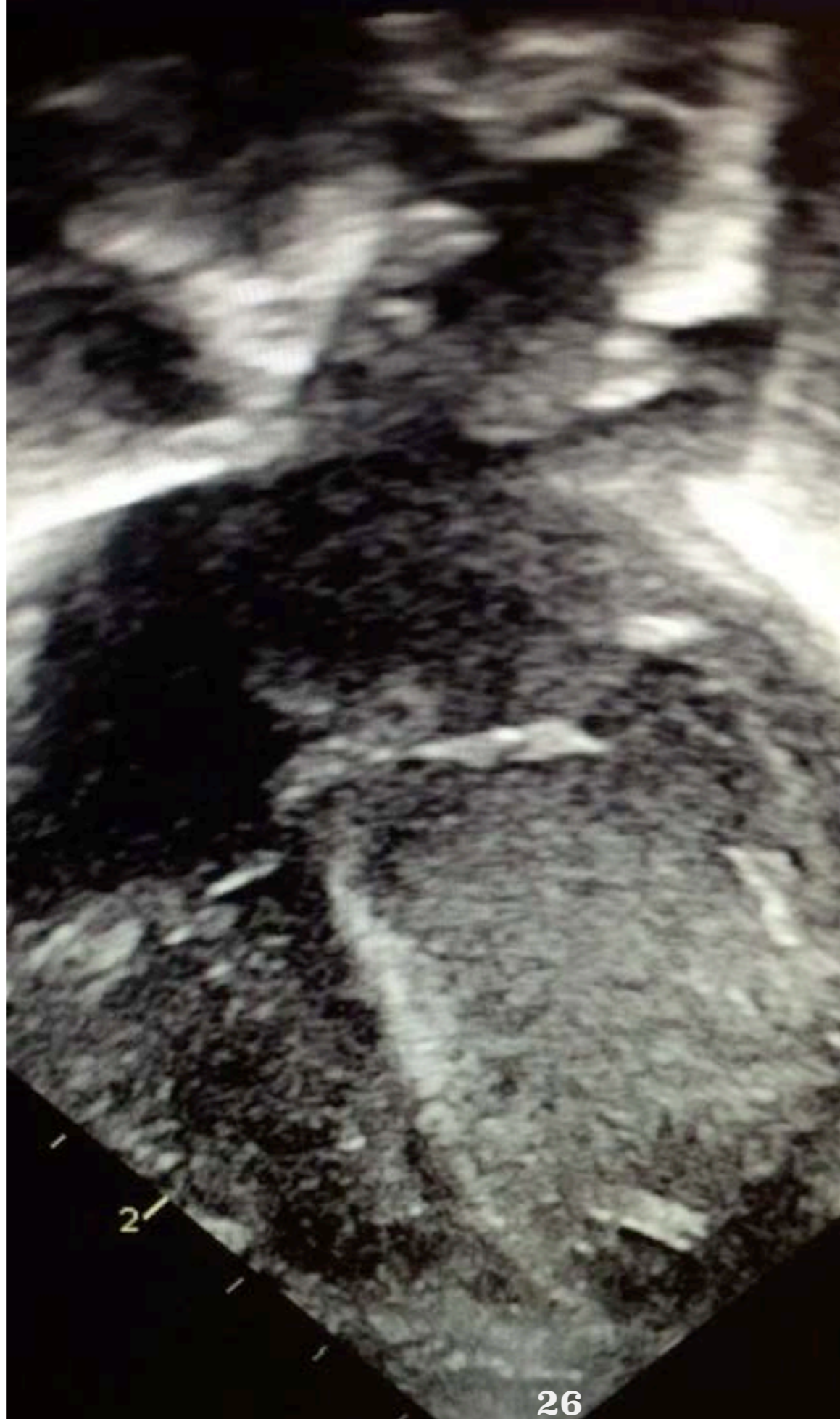24

01/04/2016 4:44:03 P



zoom 2.1 x

25



Evolution in Care of Neonate

- Since mid 20th century until today, tremendous advances in management of premies.
- Cause and effect of PDA has been questioned. Does closing the PDA really make a significant difference?
- Risks of medical treatment and even surgical ligation are still poorly defined.

Doubters

- Closure of PDA should not be attempted unless there is irrefutable evidence of harm resulting from a PDA.**
- Qualifying circumstances might include intractable hypotension or refractory congestive heart failure.**
- Despite nearly 3 decades of research, question of whether the benefits of treatments...outweigh the risks of these treatments remains unanswered.**

Recognizing the Complexity of Clinical Data

- Improved lung function after ductal closure. Some studies support. Some do not.
- End organ hypoperfusion and neonatal morbidity is less clearly defined.